


PATIENT

Bumi Roberts

SPECIES

Feline

BREED

DSH

SEX

Male Neutered

AGE

8 years

WEIGHT

9lbs

INTERPRETED BY

 Maggie Machen Lamy,
 DVM, DACVIM
 (Cardiology)

IMAGING PERFORMED BY

Dr. Karen Ebersole

HOSPITAL NAME

Scanvet

REFERRING VET

Dr. Ouellette

INVOICE

27560

DATE

11/18/22

PRESENTING CLINICAL SIGNS

History: ECG report (Idexx): Sinus tachycardia with LAFB.

ECHOCARDIOGRAM FINDINGS

2D, m-mode, color flow and doppler imaging is available. The left ventricular wall is normal in dimension with regions of mild irregularity. There is a mildly remodeled endocardium consistent with fibrosis. The papillary muscles are mildly remodeled. The left atrium is normal in size. The right atrium is normal in size. The right ventricle appears normal. The mitral valve is normal in structure and mobility. Blood flow through both the LVOT and RVOT is normal in velocity. No valve regurgitation visualized. No pleural or pericardial effusion seen. No obvious cardiac tumors.

CARDIAC CHART

FELINE CARDIAC PARAMETERS	BODY WEIGHT (kg)	HR (BPM)	IVSd (cm) (Moise, Pipers)	LVIDd (cm) (Moise, Pipers)	LWVd (cm) (Moise, Pipers)	FS (%)	EF (%)
NORMAL PARAMETER	-----	150-240	0.35-0.55	<2 (mean 1.5)	3.5-0.55	35-67	80-100
PATIENT	4.1	233	0.41	1.5	0.39	56	89
FELINE CARDIAC PARAMETERS	LA/AO (Boon)	LA/AO HEART BASE (Swe) (Abbott)	LA 2D short axis Base view (cm) (Abbott)		LVOT VEL (m/s)	RVOT VEL (m/s)	E max (m/s)
NORMAL	<1.5	<1.3	<1.2		<1.6	<1.3	<0.9
PATIENT	1.4	1.2	1.2		1.3	1.0	NM

**Note: All measurements based upon multi-modal images and methods. An average value is reported.*
 Adapted from June Boon, Veterinary Echocardiography, 1998
 Abbott J & MacLean H JVIM 2006;20: 111-119, Moise et al. Am J Vet Res 47:1476, 1986. Pipers et al. Am J Vet Res 40:882, 1979.

INTERPRETATION OF THE FINDINGS & FURTHER RECOMMENDATIONS

Overtly normal cardiac structure and function. The LV wall thickness is normal and there is no evidence of elevated left atrial pressure. There is mild remodeling and fibrosis of the left ventricular wall, which is considered a normal variant. No additional issues are identified.

Similar to other bundle branch blocks, an LAFB in cats can be indicative of structural disease or be a normal variant. Fortunately, given these findings this is likely idiopathic/benign in origin in this case.

Given these findings, no medications are indicated.

No cardiac contraindication for general anesthesia.

Recommend recheck echocardiogram in 1 year, sooner should a murmur, gallop or clinical signs of cardiac compromise be noted in the future.



PATIENT

Bumi Roberts

SPECIES

Feline

BREED

DSH

SEX

Male Neutered

AGE

8 years

WEIGHT

9lbs

INTERPRETED BY

Maggie Machen Lamy,
DVM, DACVIM
(Cardiology)

IMAGING PERFORMED BY

Dr. Karen Ebersole

HOSPITAL NAME

Scanvet

REFERRING VET

Dr. Ouellette

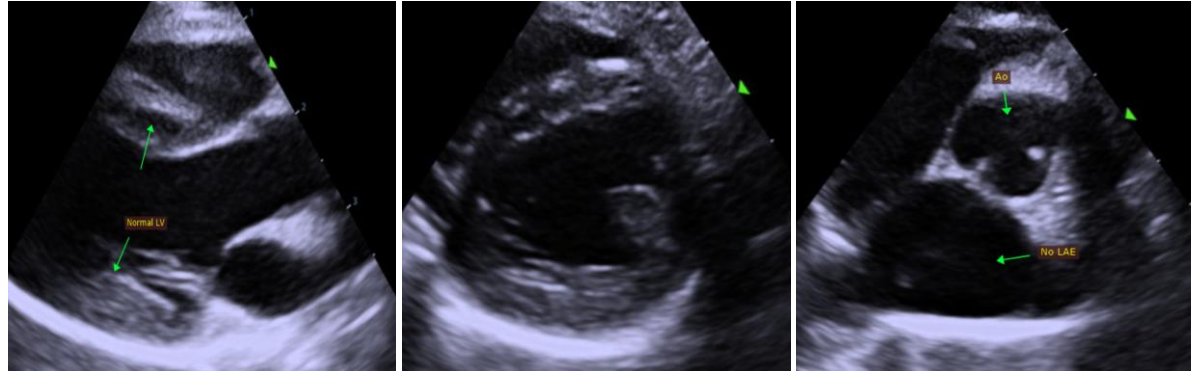
INVOICE

27560

DATE

11/18/22

IMAGES



The information and recommendations provided are based on the images presented by the referring veterinarian. No evaluation can be communicated regarding pathology that was not visible in the image/video clips provided.

Thank you for this referral. This report was generated using transcription software, and minor dictation errors may be present. If the clinical or image interpretation does not parallel your findings or if I can be of any further assistance, please contact me.

Maggie Machen Lamy, DVM
Diplomate of the American College of Veterinary Internal Medicine (Cardiology)
info@sonopath.com